

Xeroderma pigmentosum is a definite cause of Huntington's disease-like syndrome

Article (Published Version)

Lehmann, Alan (2017) Xeroderma pigmentosum is a definite cause of Huntington's disease-like syndrome. *Annals of Clinical and Translational Neurology*, 5 (1). pp. 102-108. ISSN 2328-9503

This version is available from Sussex Research Online: <http://sro.sussex.ac.uk/id/eprint/73441/>

This document is made available in accordance with publisher policies and may differ from the published version or from the version of record. If you wish to cite this item you are advised to consult the publisher's version. Please see the URL above for details on accessing the published version.

Copyright and reuse:

Sussex Research Online is a digital repository of the research output of the University.

Copyright and all moral rights to the version of the paper presented here belong to the individual author(s) and/or other copyright owners. To the extent reasonable and practicable, the material made available in SRO has been checked for eligibility before being made available.

Copies of full text items generally can be reproduced, displayed or performed and given to third parties in any format or medium for personal research or study, educational, or not-for-profit purposes without prior permission or charge, provided that the authors, title and full bibliographic details are credited, a hyperlink and/or URL is given for the original metadata page and the content is not changed in any way.

BRIEF COMMUNICATION

Xeroderma pigmentosum is a definite cause of Huntington's disease-like syndrome

Hector Garcia-Moreno¹, Hiva Fassihi², Robert P.E. Sarkany², Julie Phukan³, Thomas Warner⁴, Alan R. Lehmann⁵ & Paola Giunti^{1,2}

¹Ataxia Centre, Department of Molecular Neuroscience, University College London, Institute of Neurology, London, WC1N 3BG, United Kingdom

²National Xeroderma Pigmentosum Service, St John's Institute of Dermatology, Guy's and St Thomas' Foundation Trust, London, SE1 7EH, United Kingdom

³Neurology Department, Royal Free Hospital, London, NW3 2QG, United Kingdom

⁴Reta Lila Weston Institute of Neurological Studies, University College London, Institute of Neurology, 1 Wakefield Street, London, WC1N 1PJ, United Kingdom

⁵Genome Damage and Stability Centre, University of Sussex, Falmer, Brighton, BN1 9RQ, United Kingdom

Correspondence

Paola Giunti, Department of Molecular Neuroscience, University College London, Institute of Neurology, Queen Square House, Queen Square, London, WC1N 3BG, United Kingdom. Tel: +44(0)203-448 3100; Fax: 020 3448 4786; E-mail: p.giunti@ucl.ac.uk

The National XP Clinic in the United Kingdom is funded by the National Health Service England Highly Specialized Services. This work was also supported by the UK National Institute for Health Research Biomedical Research Centre based at Guy's and St Thomas' Foundation Trust and King's College London. PG and HGM work at University College London Hospitals/ University College London, which receives a proportion of funding from the Department of Health's NIHR Biomedical Research Centers funding scheme, and receives support from the NIHR Clinical Research Network (CRN).

Received: 5 October 2017; Revised: 7 November 2017; Accepted: 8 November 2017

Annals of Clinical and Translational Neurology 2018; 5(1): 102–108

doi: 10.1002/acn3.511

Introduction

Xeroderma pigmentosum (XP) is a rare autosomal recessive disorder, caused by mutations in the nucleotide excision repair (NER) pathway genes.^{1–5} This system repairs the DNA

Abstract

Xeroderma pigmentosum is characterized by cutaneous, ophthalmological, and neurological features. Although it is typical of childhood, late presentations can mimic different neurodegenerative conditions. We report two families presenting as Huntington's disease-like syndromes. The first case (group G) presented with neuropsychiatric features, cognitive decline and chorea. Typical lentigines were only noticed after the neurological disease started. The second case (group B) presented adult-onset chorea and neuropsychiatric symptoms after an aggressive ocular melanoma. Xeroderma pigmentosum can manifest as a Huntington's Disease-like syndrome. Classic dermatological and oncological features have to be investigated in choreic patients with negative genetic tests for Huntington's disease-like phenotypes.

structure after distortion caused by ultraviolet-induced photo-products.³ Depending on the affected gene, groups from XP-A to XP-G and XP-V have been described.⁵

Most XP patients present with cutaneous, ocular, and neurological features.^{4–8} Some groups⁹ exhibit extreme

sun sensitivity since infancy, resulting in severe sunburn to minimal sun exposure.⁴ Lentigines in sun-exposed areas and multiple cutaneous tumors are also distinctive for the disease. Secondly, ocular surface pathology, eyelid damage, and ophthalmic neoplasms are also common. Neurological manifestations occur in 20–30% of cases,⁴ usually after the cutaneous signs. Cognitive impairment, cerebellar signs, sensorineural hearing loss, and sensorimotor axonal neuropathy have been reported.^{6,9} In advanced cases, movement disorders may appear.^{7,8,10}

There is noteworthy phenotypic variability among the different XP groups and within each group.^{5,7} Thus, XP can be misdiagnosed in the absence of early dermatological features, especially in late-onset neurodegenerative phenotypes. To our knowledge, we describe here the first XP-G and XP-B families whose main neurological features tightly resemble a Huntington’s disease-like (HD-like) phenotype.

Patients and Methods

Informed consent was obtained from both patients. This study was performed in accordance with protocols approved by the Research Ethics Committee of Guy’s and St Thomas’ Foundation Trust (12/LO/0325). The diagnostic techniques have been previously described.^{5,11} Pedigrees were designed using the CeGaT Pedigree Chart Designer tool[®].

Results

Case 1

The first case was a 63-year-old lady who had suffered from sun sensitivity since childhood, with two episodes of severe sunburn. She had not received any prior neuropsychiatric treatments, including dopamine blocking or

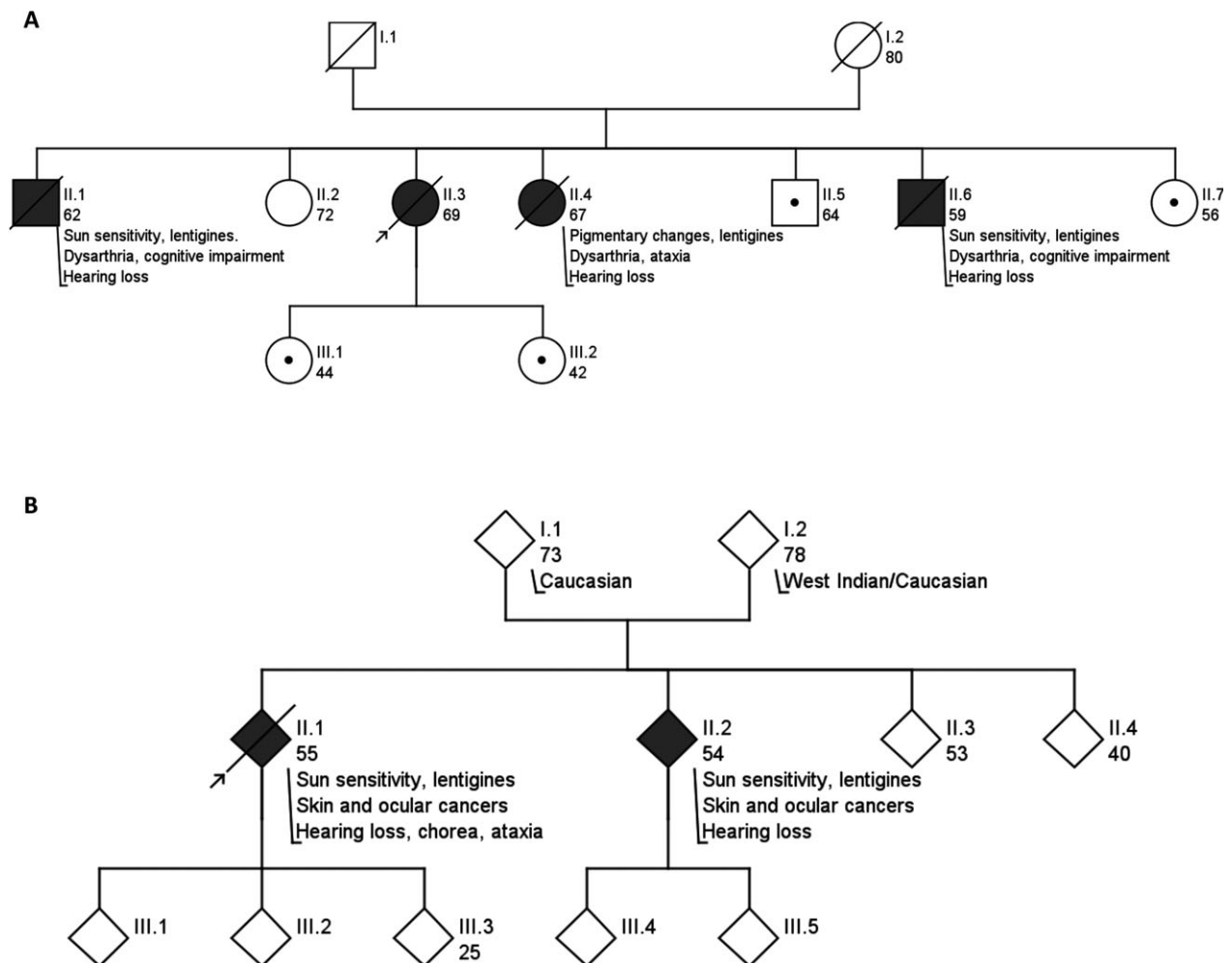


Figure 1. **A:** case 1 pedigree (member order, age, phenotype/comments). The subjects with a dot are carriers for the mutation. **B:** case 2 pedigree (member order, age, phenotype/comments). The pedigree was altered to preserve anonymity.

depleting agents. First neurological symptoms appeared when she was 53, as mild short-term memory impairment, and loss of her standards of personal hygiene. Two years later, she complained of hearing loss and some hyperkinetic movements were noted. During the ensuing 5 years, she experienced progressive deterioration in neuropsychiatric symptoms with disinhibition, apathy and neglect of personal hygiene; as well as worsening of balance and involuntary movements, resulting in multiple falls. Subsequently, she was referred to a movement disorder specialist, who found she had generalized chorea and commenced a treatment with 7.5 mg olanzapine, with improvement of the hyperkinetic movements.

When assessed in our clinic, she was found to have extensive lentigines and hypopigmented macules at sun-exposed sites. She had photophobia, lagophthalmos, mild keratopathy and sunken eyes. Neurologically, she was disoriented and had poor executive function. She had a full range of external ocular movements, with nystagmus, slow initiation of saccades, and sluggish pupils. She showed pyramidal features in the lower limbs (weakness, hyperreflexia and Babinski's sign) and cerebellar signs in the upper limbs (dysmetria and intentional tremor). The gait was broad-based with mild camptocormia and preserved arm swing. There was chorea in the fingers, as well as, neck and trunk dystonia. Her clinical status progressively declined with hallucinations, delusions, disrupted behavior and loss of independent gait (Video S1). She died at the age of 69, following a pulmonary thromboembolism.

Her parents came from the same village in Cyprus. The patient was the third of seven siblings. Two siblings presented sun sensitivity, lentigines, and developed cognitive impairment and slurred speech in their 50s. They died at the age of 62 and 59. The fourth sibling was a lady who showed pigmentary changes and lentigines, as well as slurred speech and cerebellar ataxia from her 50s. Later, she developed chorea and dementia. All the three affected siblings developed hearing impairment. The other siblings and the patient's daughters were unaffected (Fig. 1A).

Her brain MRI (Fig. 2) showed nonspecific atrophy of the brain and cerebellum without involvement of the caudate nuclei. Nerve conduction studies were normal. Pure tone audiometry revealed bilateral sensorineural hearing loss. Three blood films for acanthocytes were negative, as well as lupus anticoagulant and anticardiolipin antibodies. An extensive battery of genetic tests yielded negative results, including: HD; familial prion disease (*PRNP*); HDL-2 (junctophilin-3); *C9orf72* expansion; dentatorubral-pallidolysian atrophy (DRPLA, atrophin-1); spinocerebellar ataxias (SCA) 1, 2, 3, 6, 7, 12, and 17. Owing to the significant cutaneous involvement, the suspicion of XP was raised and an unscheduled DNA synthesis assay was performed. Her skin fibroblasts were defective

for the NER system, showing less than 15% of repair activity after ultraviolet radiation. XP genes sequencing showed a homozygous single nucleotide substitution (c.869T>A) in exon 7 of the *XP-G/ERCC5* gene. This is predicted to cause a single amino acid substitution (p.Ile290Asn) and has been previously reported as a pathogenic missense mutation.⁵ The patient was therefore diagnosed with late-onset XP-G. Her affected sister was homozygous for the same mutation. Two of the unaffected siblings were carriers.

Case 2

The second case was a 52-year-old patient who was easily sunburned since childhood, and had lentigines since the age of 2 years. Regarding previous pharmacological treatments, no prior dopamine antagonists were noted. A melanoma in the right corneal limbus was detected at the age of 22 and the first of multiple nonmelanoma cancers was diagnosed 7 years later. Due to a recurrence of the melanoma, an enucleation of the eye was performed at the age of 36 years old. Neurologically, the patient presented at the age of 17 with severe bilateral sensorineural hearing loss. On examination, the patient had dense lentigines and hypopigmented macules on sun-exposed sites such as the face, neck and arms. There were also numerous cherry angiomas at those sites. Choreic movements, with grimaces and emotional lability were noted. Despite normal tone and power throughout, pyramidal signs were found (brisk reflexes and bilateral Babinski's sign). The upper limbs showed dysmetria and intentional tremor. There

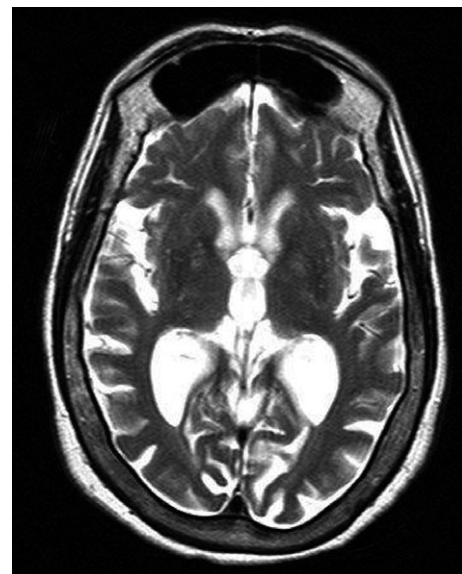

Figure 2. T2-weighted image MRI from case 1.

Table 1. Features of the main HD-like syndromes compared to XP cases.^{11,13-20}

	Spinocerebellar ataxia type-17		Huntington disease-like 1		Huntington disease-like 2		DRPLA	Neuroferritinopathy		Chorea-Acanthocytosis		XP-F	XP-G	XP-B
	AD	Expanded CAG/CAA	AD	Expanded GTC/CAG	AD	Expanded GTC/CAG		AD	Expanded CAG	AD	Expanded CAG			
Inheritance	AD		AD		AD		AD		AD		AR		AR	
Gene	<i>TBP</i>		<i>JPH3</i>		<i>ATN1</i>		<i>FTL</i>		<i>FTL</i>		<i>VPS13A</i>		<i>ERCC5</i>	
Mutation	Expanded CAG/CAA		Expanded GTC/CAG		Expanded CAG		Adenine insertion in exon 4		Adenine insertion in exon 4		Various (p-Arg799Trp)		Various (p.Ile290Asn)	
Ethnicity	Caucasian, Asian		Black South African		Japan		France		Japan, French-Canadian		Japan, French-Canadian		Greek Cypriot	
Onset	3-75 y.o.		20-40 y.o.		20-30 y.o.		40 y.o.		20-30 y.o.		30-47 y.o.		45 y.o.	
Survival	N/R		10-20 y.		10-15 y.		N/R		15-20 y.		>20 y.		>20 y.	
Movement disorders	Chorea (20%)		Chorea, rigidity		Chorea		Chorea, dystonia, PD-like		Chorea, dystonia, tics		Chorea		Chorea	
Cerebellar signs	++ (>90%)		-		++		-		-		++		++	
Cognitive involvement	++ (100%)		++ (100%)		++		++		++		+		++	
Psychiatric symptoms	-		++ (100%)		++		-		++		-		++	
Seizures	+ (50%)		-		+ (young onset)		-		+ (50%)		-		-	
Other features			No peripheral nerve or muscle abnormality		Myoclonus (young onset)		Action-specific orofacial dystonia		Tongue protrusion and biting. Neuropathy. Amyotrophy.		Mild sun sensitivity, freckles. Skin tumors.		Sun sensitivity, freckles. Ocular disease. SN hearing loss.	
MRI	Cerebellar atrophy. Rim enhancement of putamen		Atrophy of caudate and cerebral hemispheres		T2WI-hyperintense white matter lesions and PC atrophy		T2*WI-hypointense signal in BG and thalamus		Cerebellar, cortical and subcortical atrophy.		Cerebellar, cortical and subcortical atrophy.		Cortical and cerebellar atrophy.	

AD, autosomal dominant; AR, autosomal recessive; *TBP*, TATA-box binding protein; *PRNP*, prion protein (PrP); *JPH3*, junctophilin-3; *ATN1*, atrophin-1; *FTL*, ferritin light chain; *VPS13A*, chorein; *ERCC4*, excision repair cross-complementing protein-4; *ERCC5*, excision repair cross-complementing protein-5; *ERCC3*, excision repair cross-complementing protein-3; y.o., years old; y., years; N/R, not reported; PD-like, Parkinson's disease-like; -, not prominent; +, common; ++, very frequent; SN, sensorineural; T2WI, T2-weighted image MRI; PC, pontocerebellar; T2*WI, T2*(Echo gradient)-weighted image MRI; BG: Basal Ganglia.

was also some numbness in the right foot and a broad-based gait. One year later, the patient complained of neck pain spreading to the left arm. After several investigations, she was diagnosed with a left upper lobe lung neoplasm. The patient died at the age of 55, due to complications of metastatic lung cancer.

One of the patient's siblings also had multiple skin tumors, early deafness and required enucleation of one eye due to melanoma (Fig. 1B).

The patient's MRI showed diffuse cerebral and cerebellar atrophy. Genetic analysis revealed heterozygous mutations in the *XP-B/ERCC3* gene (namely, c.296T>C, resulting in the missense mutation p.Phe99Ser; and c.1273C>T, producing the nonsense mutation p.Arg425X), both of which have been previously reported.^{5,11} Therefore, the diagnosis of XP-B was made at the age of 43. The affected sibling shared the same genotype.

Discussion

Both index cases exemplify the challenge of XP diagnosis in late-onset neurodegenerative phenotypes, especially in the presence of inconspicuous skin manifestations.

Neurological symptoms in XP patients can constitute a major source of disability and can carry higher rates of mortality in patients, compared to those without neurological involvement (37% vs. 29%).¹² While strict photoprotection can prevent cutaneous and ophthalmological complications, there are no treatments to slow down the progression of the neurological disease. Neurologists should proactively investigate the presence of lentiginos in sun-exposed areas (face, neck, hands...), a previous history of easy or severe sunburn, or previous skin cancers, even if the first cutaneous signs occurred in childhood.

Both cases fulfilled the criteria for HD-like syndromes¹³: presence of movement disorders consistent with HD, a negative genetic test for HD, the occurrence of cognitive impairment and/or behavioral disturbances, and a positive family history for analogous neurological disorders. HD-like syndromes are challenging entities, since a definite genetic diagnosis is reached in less than 3% of cases.¹⁴ Previously, the principal identified diseases were *C9orf72* expansion, SCA 17, HDL-1 (mutations in *PRNP*) and HDL-2 (mutations in *junctophilin-3*). Conditions such as DRPLA, neuroferritinopathy or chorea-acanthocytosis can also present as HD-like disorders. The main characteristics of these conditions are summarized in Table 1.^{11,13–20}

We have presented here the occurrence of chorea and cognitive impairment in patients with mutations in different genes of the NER pathway (*ERCC5* and *ERCC3*). In a recent report by Carré et al.,¹⁵ two XP-F patients (with

mutations in the *ERCC4* gene) with chorea and cerebellar ataxia were also described. Consequently, we reinforce the notion that XP should be included in the differential diagnosis of HD-like syndromes. The suspicion of XP should be raised if there is a history of skin disorder, even as mild as in the first presented case, and alternative genetic testing is negative.

The cases in this report illustrate novel pathophysiological mechanisms. Since a DNA repair disorder can mimic HD, the NER pathway might be of importance for both conditions. Apart from its role against photoproducts, the NER system also repairs the damage caused by inner sources, such as oxidative damage.³ Due to the NER system impairment, both nuclear and mitochondrial DNA (mtDNA) can accumulate mutations. It is known that mtDNA damage and mitochondrial dysfunction occur in HD.² Therefore, NER disruption might contribute to the mitochondrial damage and neuronal loss in HD. Moreover, XP-B and XP-G are components of the transcription factor IIH (TFIIH),^{21,22} which participates in transcription processes. Dysregulation of this mechanism might contribute to the neurodegeneration in XP.

Our cases emphasize the occurrence of hyperkinetic abnormal movements in DNA repair disorders. Subtle dystonia or tremor is often apparent in XP patients, even in those cases without overt neurological manifestations (PG observation). Recent reports have illustrated the relation between cerebellar atrophy and different movement disorders in mitochondrial conditions²³ and HD.²⁴ It is unclear whether the NER pathway could be particularly relevant for basal ganglia metabolism or whether the hyperkinetic movement disorders are a consequence of the cerebellar dysfunction: further studies are needed to elucidate the underlying pathogenesis.

Acknowledgments

The authors thank the study participants and their relatives, as well as Arron Cook and Michael Parkinson for the review of the manuscript. The National XP Clinic in the United Kingdom is funded by the National Health Service England Highly Specialized Services. This work was also supported by the UK National Institute for Health Research Biomedical Research Centre based at Guy's and St Thomas' Foundation Trust and King's College London. PG and HGM work at University College London Hospitals/University College London, which receives a proportion of funding from the Department of Health's NIHR Biomedical Research Centers funding scheme, and receives support from the NIHR Clinical Research Network (CRN).

Author's Contribution

Hector Garcia-Moreno: Research Project: B. Organization, C. Execution. Manuscript: A. Writing of the first draft, B. Review and Critique. Hiva Fassihi: Research Project: B. Organization, C. Execution. Manuscript: B. Review and Critique. Robert P.E. Sarkany: Research Project: B. Organization, C. Execution. Manuscript: B. Review and Critique. Julie Phukan: Research Project: B. Organization. Manuscript: A. Writing of the first draft. Prof Thomas Warner: Research Project: B. Organization. Manuscript: B. Review and Critique. Prof Alan R. Lehmann: Research Project: B. Organization, C. Execution. Manuscript: B. Review and Critique. Paola Giunti: Research project: A. Conception, B. Organization, C. Execution. Manuscript: B. Review and critique.

Conflict of Interest

HGM has received financial support from Medical Research Council, and from Actelion Pharmaceuticals UK for travel to scientific symposiums. TW have received funding from Britannia Pharmaceuticals, Medical Research Council, Reta Lila Weston Medical Trust and Corticobasal Degeneration Solutions Inc. PG has received financial support from Actelion Pharmaceuticals Inc, Pfizer, Reata Pharmaceuticals Inc, Ataxia UK and Medical Research Council. PG and HGM work at University College London Hospitals/University College London, which receives a proportion of funding from the Department of Health's NIHR Biomedical Research Centers funding scheme, and receives support from the NIHR Clinical Research Network (CRN). The other authors have nothing to report.

REFERENCES

- Rass U, Ahel I, West SC. Defective DNA repair and neurodegenerative disease. *Cell* 2007;130:991–1004.
- Jeppesen DK, Bohr VA, Stevnsner T. DNA repair deficiency in neurodegeneration. *Prog Neurobiol* 2011;94:166–200.
- Rao KS. Mechanisms of disease: DNA repair defects and neurological disease. *Nat Clin Pract Neurol* 2007;3:162–172.
- Lehmann AR, McGibbon D, Stefanini M. Xeroderma pigmentosum. *Orphanet J Rare Dis* 2011;6:70.
- Fassihi H, Sethi M, Fawcett H, et al. Deep phenotyping of 89 xeroderma pigmentosum patients reveals unexpected heterogeneity dependent on the precise molecular defect. *Proc Natl Acad Sci USA* 2016;113:E1236–E1245.
- Mimaki T, Itoh N, Abe J, et al. Neurological manifestations in xeroderma pigmentosum. *Ann Neurol* 1986;20:70–75.
- Anttinen A, Koulu L, Nikoskelainen E, et al. Neurological symptoms and natural course of xeroderma pigmentosum. *Brain* 2008;131:1979–1989.
- Kraemer KH, Lee MM, Scotto J. Xeroderma pigmentosum: Cutaneous, ocular, and neurologic abnormalities in 830 published cases. *Arch Dermatol* 1987;123:241–250.
- Sethi M, Lehmann AR, Fawcett H, et al. Patients with Xeroderma Pigmentosum complementation groups C, E and V do not have abnormal sunburn reactions. *Br J Dermatol* 2013;169:1279–1287.
- Adamec D, Xie J, Poisson A, et al. Xeroderma pigmentosum: a rare cause of chorea. *Rev Neurol (Paris)* 2011;167:837–840.
- Oh KS, Khan SG, Jaspers NGJ, et al. Phenotypic heterogeneity in the XPB DNA helicase gene (ERCC3): xeroderma Pigmentosum without and with Cockayne syndrome. *Hum Mutat* 2006;27:1092–1103.
- Bradford PT, Goldstein AM, Tamura D, et al. Cancer and neurologic degeneration in Xeroderma Pigmentosum: long term follow-up characterizes the role of DNA repair. *J Med Genet* 2011;48:168–176.
- Wild EJ, Tabrizi SJ. Huntington's disease phenocopy syndromes. *Curr Opin Neurol* 2007;20:681–687.
- Wild EJ, Mudanohwo EE, Sweeney MG, et al. Huntington's disease phenocopies are clinically and genetically heterogeneous. *Mov Disord* 2008;23:716–720.
- Carré G, Marelli C, Anheim M, et al. Xeroderma pigmentosum complementation group F: a rare cause of cerebellar ataxia with chorea. *J Neurol Sci* 2017;376:198–201.
- Moore RC, Xiang F, Monaghan J, et al. Huntington disease phenocopy is a familial prion disease. *Am J Hum Genet* 2001;69:1385–1388.
- Sunami Y, Koide R, Arai N, et al. Radiologic and neuropathologic findings in patients in a family with dentatorubral-pallidoluysian atrophy. *AJNR Am J Neuroradiol* 2011;32:109–114.
- Chinnery PF, Crompton DE, Birchall D, et al. Clinical features and natural history of neuroferritinopathy caused by the FTL1 460InsA mutation. *Brain* 2007;130:110–119.
- Jung HH, Danek A, Walker RH. Neuroacanthocytosis Syndromes. *Orphanet J Rare Dis* 2011;6:68.
- Hensman Moss DJ, Poulter M, Beck J, et al. C9orf72 expansions are the most common genetic cause of Huntington disease phenocopies. *Neurology* 2014;82:292–299.
- Compe E, Egly JM. Nucleotide excision repair and transcriptional regulation: TFIIH and beyond. *Annu Rev Biochem* 2016;85:265–290.
- Ito S, Kuraoka I, Chymkowitch P, et al. XPG stabilizes TFIIH, allowing transactivation of nuclear receptors: implications for cockayne syndrome in XP-G/CS Patients. *Mol Cell* 2007;26:231–243.
- Schreglmann SR, Riederer F, Galovic M, et al. Movement disorders in genetically confirmed mitochondrial disease

and the putative role of the cerebellum. *Mov Disord* 2017; <https://doi.org/10.1002/mds.27174>.

24. Rees EM, Farmer R, Cole JH, et al. Cerebellar abnormalities in huntington's disease: a role in motor and psychiatric impairment? *Mov Disord* 2014;29:1648–1654.

Supporting Information

Additional Supporting Information may be found online in the supporting information tab for this article:

Video S1. *Segment 1.* Dystonic posture of the neck (with predominant laterocaput to the left and elevation of right shoulder) and the trunk was observed. The patient showed frequent blinking and choreic movements in the oromandibular area and the four limbs. In addition, lentigines in the face, the neck and hands are visible. *Segment 2.* The patient needed constant bilateral support of an accompanying person due to her imbalance. It is remarkable the broad-based gait, with small steps and difficulty in turning, as well as the stoop position.